

REVIEW OF URINARY SYSTEM

Sp95

URINARY ORGANS

kidneys

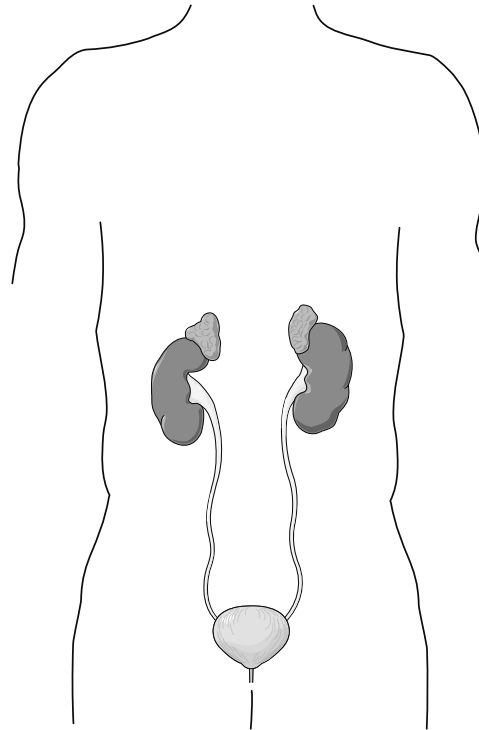
ureters

urinary bladder

urethra

urethral orifice (females)

urogenital orifice (males)



NEPHRON

glomerulus

Bowman's capsule

proximal convoluted tubule

loop of Henle

distal convoluted tubule

collecting duct

